

Common Endoscopic Spine Terms

Ablation: A method that may be used to reduce certain kinds of chronic pain by preventing transmission of pain signals. It is a safe procedure in which a portion of nerve tissue is disabled which causes an interruption in pain signals and will reduce or eliminate the pain in that area.

Disc Herniation: Also known as a slipped disc, is a medical condition affecting the spine in which a tear in the outer, fibrous ring of an intervertebral disc allows the soft, central portion to bulge out beyond the damaged outer rings.

Discectomy: Surgical removal of the whole or a part of an intervertebral disc.

Foraminotomy: A foraminotomy is a decompression surgery that is performed to enlarge the passageway where a spinal nerve root exits the spinal canal. The term foraminotomy is derived from the medical term for a hollow passageway (foramen).

Laminotomy: A laminotomy is a procedure that removes part of the lamina of a vertebral arch in order to relieve pressure in the vertebral canal.

Rhizotomy: a surgical procedure to sever nerve roots in the spinal cord. The procedure effectively relieves chronic back pain and muscle spasms. For spinal joint pain, a facet rhizotomy may provide lasting low back pain relief by disabling the sensory nerve at the facet joint.

Spinal Stenosis: Narrowing of the anatomy which causes pressure on the spinal cord and the nerves within the spine. It commonly occurs in the neck and lower back. The condition is often caused by age-related wear and tear. Symptoms, if they occur, include pain, numbness, muscle weakness, and impaired bladder or bowel control.

Potential Benefits of Endoscopic Surgery

- Outpatient Procedure
- Less Operative Time
- Local Anesthetic Can Be Used
- Minimal Risk Of Infection
- Minor Skin Incision
- Minimal Access Procedure
- Multiple Treatment Options
- Quick Relief Of Symptoms
- Can Treat Multiple Diagnosis
- Earlier Return To Activities
- Fewer Scars, Less Wound And Muscle Pain
- Preserves All Additional Surgical Options



2455 Grand Avenue, Baldwin, NY 11510
(516) 277-9000 • Fax (516) 277-9001
www.elliquence.com

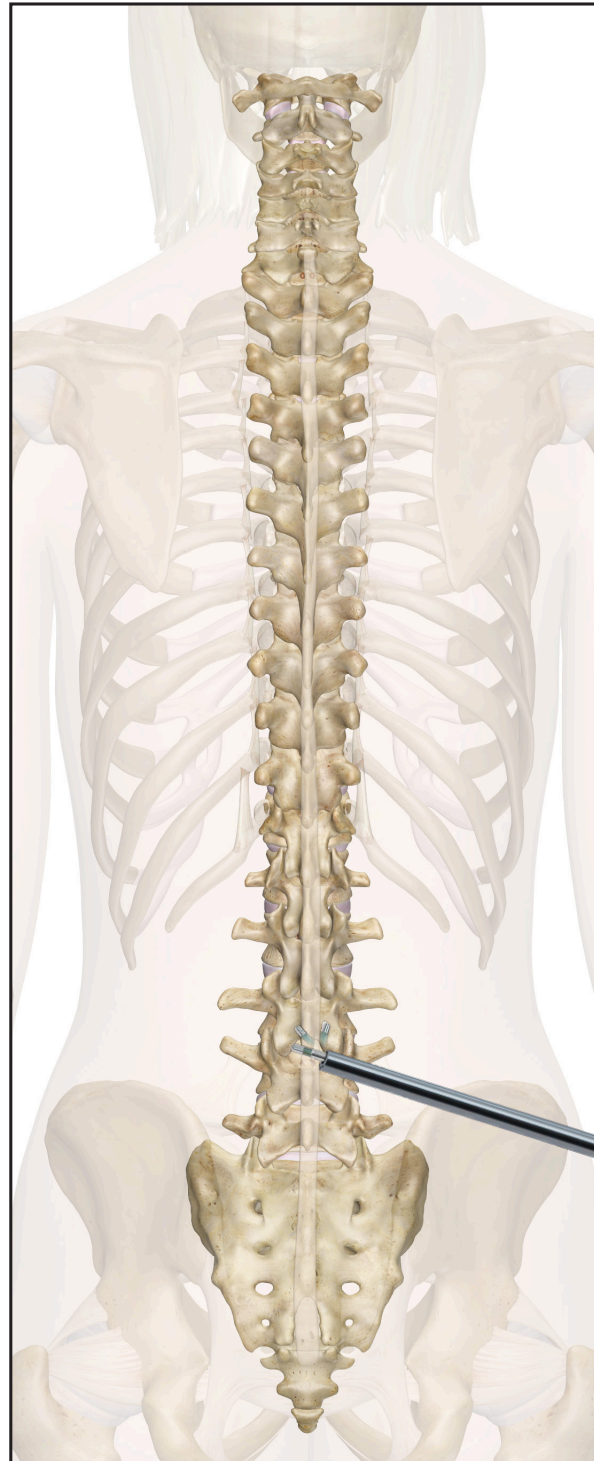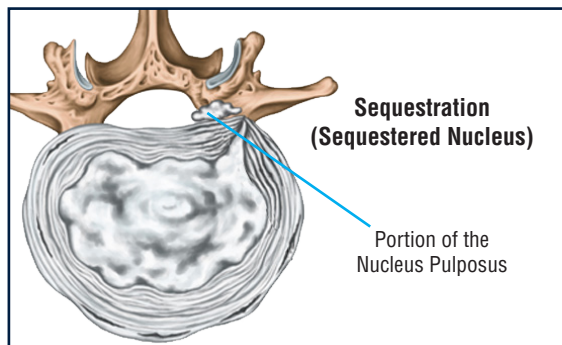
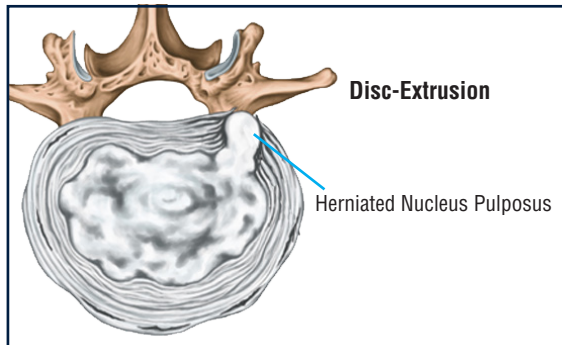
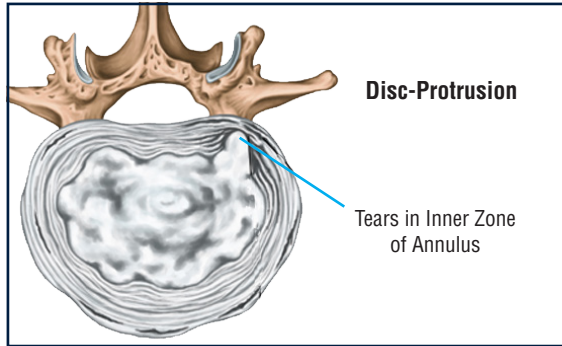


Endoscopic Spine Treatment
Patient Information

Endoscopic Spine Procedures

Unlike open surgery, endoscopic spine surgery allows access to spinal pathology through a tiny opening to preserve tissue. With an endoscopic procedure, patients are able to be treated and return to every day activities quicker than if they had an open surgery procedure. Much like knee and shoulder arthroscopy, spine endoscopy uses an endoscope to show the surgeon all the anatomy without causing collateral damage to healthy tissue. Your physician may choose to provide this unique solution for addressing a variety of spine pathologies that are addressed through a minimally invasive approach.

Different types of Herniations

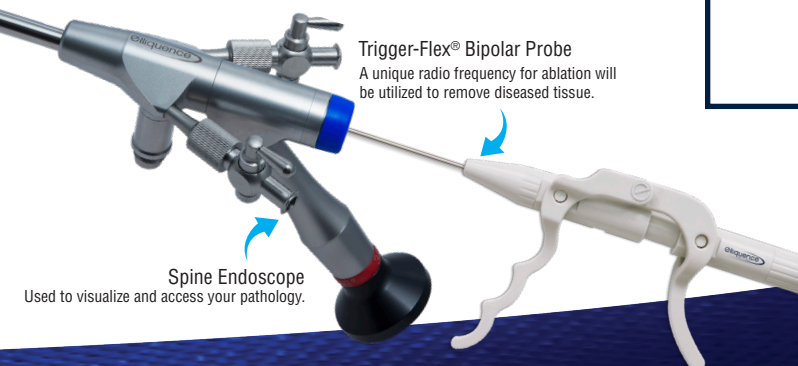
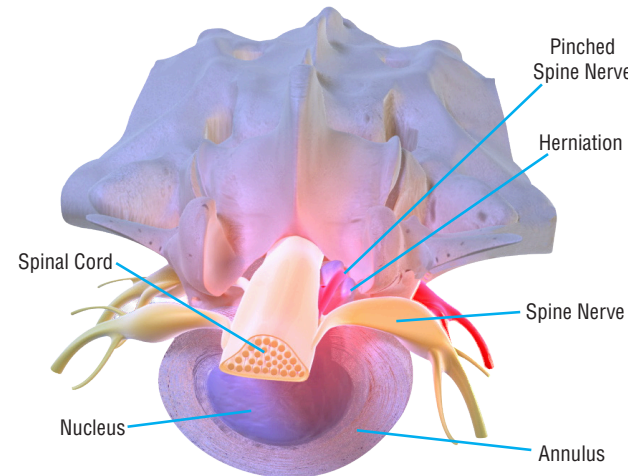


Why would I require an endoscopic procedure?

Some common identifiers for back surgery are low back pain and pain radiating down your leg (sciatica). This indicates that you may have a herniated disc which can be treated endoscopically. Simple aging of the spine may create the need for an endoscopic procedure. As we grow in age, the spine can decrease in strength and can cause a collapsed disc, causing pressure on nerves that results in pain.

Procedure Overview

Spine endoscopy allows access to the anatomy and is done with a series of small instruments that ultimately allow for the placement of a working channel scope to visualize the pathology that is causing the pain and correct it, or remove it. This can be related to disc herniations or bony overgrowth (hypertrophy). Patients are generally under light anesthesia and are able to return home the same day with restricted activity.



Anatomy of the Spine

There are 7 cervical (neck), 12 thoracic (chest), five lumbar (back), and five sacral (tail) vertebrae. The spinal cord has nerve roots that exit the spinal canal between the vertebral bodies. Spinal cord segments or levels house the nerve roots that pass through them but are not always situated at the corresponding vertebral levels.

